



Direct tracheobronchopexy to correct airway collapse due to severe tracheobronchomalacia: Short-term outcomes in a series of 20 patients



Sigrid Bairdain^{a,1}, Charles Jason Smithers^{a,1}, Thomas E. Hamilton^a, David Zurakowski^{a,b}, Lawrence Rhein^c, John E. Foker^d, Christopher Baird^{e,2}, Russell W. Jennings^{a,*,2}

^a Department of Pediatric Surgery, Boston Children's Hospital, Harvard Medical School, Boston, MA, USA

^b Department of Anesthesiology, Perioperative and Pain Medicine, Boston Children's Hospital, Boston, MA, USA

^c Department of Pulmonology, Boston Children's Hospital, Harvard Medical School, Boston, MA, USA

^d University of Minnesota, Minneapolis, MA, USA

^e Department of Cardiovascular Surgery, Boston Children's Hospital, Harvard Medical School, Boston, MA, USA

ARTICLE INFO

Article history:

Received 5 March 2015

Accepted 10 March 2015

Key words:

Apparent life threatening events (ALTE)

Pneumonias

Tracheobronchopexy

ABSTRACT

Purpose: Tracheobronchomalacia (TBM) is associated with esophageal atresia, tracheoesophageal fistulas, and congenital heart disease. TBM results in chronic cough, poor mucous clearance, and recurrent pneumonias. Apparent life-threatening events or recurrent pneumonias may require surgery. TBM is commonly treated with an aortopexy, which indirectly elevates trachea's anterior wall. However, malformed tracheal cartilage and posterior tracheal membrane intrusion may limit its effectiveness. This study describes patient outcomes undergoing direct tracheobronchopexy for TBM.

Methods: The records of patients that underwent direct tracheobronchopexy at our institution from January 2011 to April 2014 were retrospectively reviewed. Primary outcomes included TBM recurrence and resolution of the primary symptoms. Data were analyzed by McNemar's test for matched binary pairs and logistic regression modeling to account for the endoscopic presence of luminal narrowing over multiple time points per patient.

Results: Twenty patients were identified. Preoperative evaluation guided the type of tracheobronchopexy. 30% had isolated anterior and 50% isolated posterior tracheobronchopexies, while 20% had both. Follow-up was 5 months (range, 0.5–38). No patients had postoperative ALTEs, and pneumonias were significantly decreased ($p = 0.0005$). Fewer patients had tracheobronchial collapse at postoperative endoscopic exam in these anatomical regions: middle trachea ($p = 0.01$), lower trachea ($p < 0.001$), and right bronchus ($p = 0.04$).

Conclusion: The use of direct tracheobronchopexy resulted in ALTE resolution and reduction of recurrent pneumonias in our patients. TBM was also reduced in the middle and lower trachea and right mainstem bronchus. Given the heterogeneity of our population, further studies are needed to ascertain longer-term outcomes and a grading scale for TBM severity.

© 2015 Elsevier Inc. All rights reserved.

Tracheobronchomalacia (TBM) is often associated with esophageal atresia (EA), tracheoesophageal fistula (TEF), and congenital heart disease (CHD), and may result in chronic cough, poor mucous clearance, and recurrent pneumonias [1]. Furthermore, the adverse effects of TBM are heightened in such patient groups as esophageal atresia, congenital heart disease, and cystic fibrosis patients given the potential for airway obstruction, frequent infections, a potential for more limited physiological reserve, and mortality [2]. In the most severe cases, apparent life-threatening events (ALTE) or recurrent respiratory decompensation may require emergent intervention.

Coaptation of the airways with anterior and posterior collapse in spontaneously breathing patients indicates severe TBM [1–9]. TBM is

commonly treated with aortopexy, which indirectly elevates the anterior wall of the trachea [1]. However, in our experience, anteriorly malformed tracheal cartilage and posterior tracheal membrane intrusion may limit the effectiveness of aortopexy in some cases and may require further interventions. Therefore, we reviewed a series of patients who underwent a more direct anterior and/or posterior tracheobronchopexy for severe TBM to determine the following: (1) the resolution of the symptoms that warranted the operative procedure; and, (2) to provide bronchoscopic evidence of the effectiveness of the direct tracheobronchopexy procedure.

1. Materials

1.1. Basic demographics and multidisciplinary team approach

Following institutional review board approval (IRB-P00010423), all patients who underwent direct tracheobronchopexy from January 2011 to April 2014 at Boston Children's hospital were retrospectively

* Corresponding author at: Department of Pediatric Surgery, Boston Children's Hospital, Esophageal Atresia Program, 300 Longwood Avenue, Fegan 3, Boston MA, 02115, USA. Tel.: +1 617 355 3038.

E-mail address: Russell.jennings@childrens.harvard.edu (R.W. Jennings).

¹ Indicates co-first authors.

² Indicates co-senior authors.

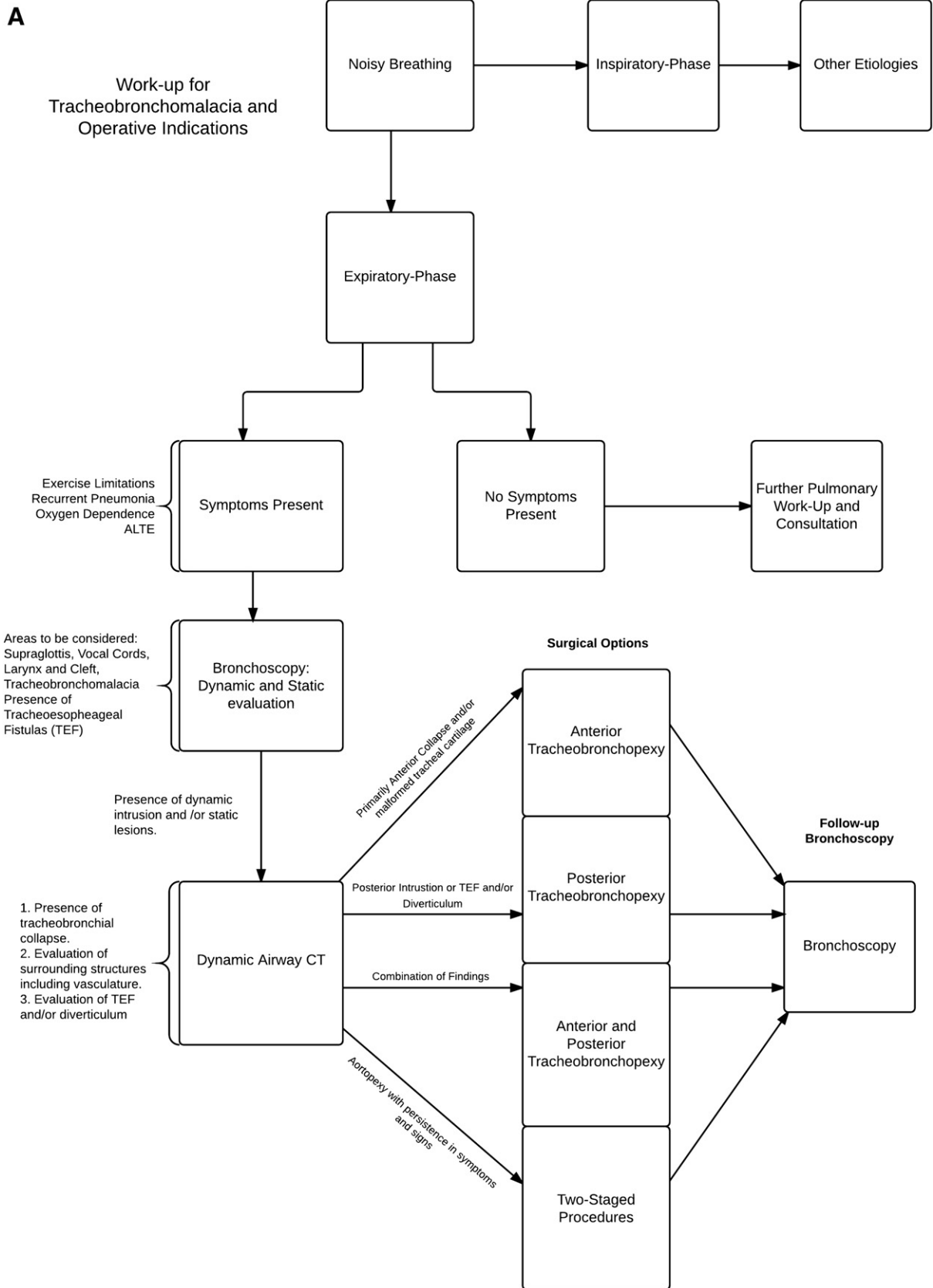
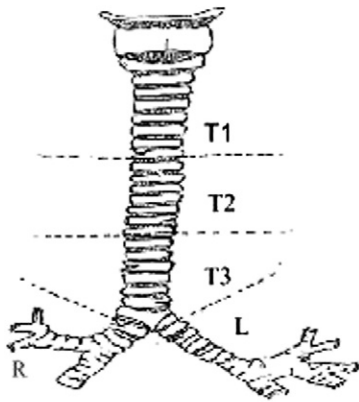


Fig. 1. A: Algorithm for work-up of tracheobronchomalacia. B: Standardized scoring assessment.

B Standardized Scoring System



Location		Character			
		Normal	Anterior collapse	Posterior intrusion	Both
Trachea					
	Upper third (T1)				
	Middle third (T2)				
	Lower third (T3)				
Main bronchi					
	Right				
	Left				

Fig. 1 (continued).

reviewed. Patient characteristics, perioperative characteristics and medications, computer tomography (CT) scans and endoscopic evaluations, surgical technique, and complications were all collected. Information regarding reoperations was also collected. Patients were excluded if they had other procedures performed to address TBM.

Our multidisciplinary team consisted of pediatric surgeons, pediatric cardiothoracic surgeons, and a pediatric pulmonologist. A flow diagram of the preoperative decision-making processes and operative indications were illustrated in Fig. 1A. Holistic evaluation included evaluation of medical history, congruency of endoscopic and CT imaging results, and individualized surgical plans based on the aforementioned findings. Emphasis was on limiting the number of reoperations in these children, as well CT scans.

1.2. Endoscopic evaluation and CT imaging

Preoperative, intraoperative, and postoperative bronchoscopies were performed by the primary surgeons involved. Anatomic regions were evaluated in a standardized fashion [10]. In brief, the trachea was evaluated by anatomical region and collapse. Anatomic regions were further classified into upper, middle, and lower trachea; and, right and left mainstem bronchus. Endoscopic exam evaluated whether there was the presence of any tracheobronchomalacia pretracheobronchopexy and posttracheobronchopexy. Fig. 1B illustrated the standardized bronchoscopic scoring system as it pertained to the tracheobronchial tree. Presence and predominance of anterior collapse and/or posterior intrusion was coded as either present (code 1) or absent (code 0). Additional CT imaging was performed by discretion of the operating surgeons and dictated by coexisting medical conditions.

1.3. Surgical Technique

Primarily endoscopic exams and preoperative imaging guided the type of tracheobronchopexy performed and the surgeon determined the approach. Generally patients with associated esophageal disease underwent primary thoracotomy while those with cardiac disease underwent sternotomy. For those with multiple disease entities present, surgeons favored addressing all concerns during one operative case avoiding reoperative cases. Tracheobronchopexy was performed following thoracotomy or sternotomy, mobilization of the esophagus,

thoracic duct and/or aorta. In patients undergoing sternotomy, the ductal ligament was frequently divided in order to completely mobilize the ascending, transverse arch and descending aorta.

Posterior tracheobronchopexy was performed by passing pledgeted polypropylene sutures through the posterior tracheal membrane and securing it to the anterior spinal ligament under direct endoscopic guidance. Anterior tracheobronchopexy was completed by elevating the anterior wall of the trachea and/or bronchi by passing pledgeted sutures through the rings under direct endoscopic guidance. In patients undergoing sternotomy, these sutures were then passed through the sternum and secured under direct endoscopic guidance following sternal closure.

1.4. Statistical Analysis

Logistic regression modeling was applied using a generalized estimating equations (GEE) approach to account for the endoscopic presence of tracheobronchomalacia over repeated measures within the same patient with the Wald chi-square test for assessing significance [11]. At latest follow-up, recurrent pneumonia and need for supplemental oxygen were determined by McNemar's paired test for binary data [12]. Power analysis indicated that the sample size of 18 patients provided 80% power to detect changes in airway collapse at postoperative evaluation for each of five anatomical regions using logistic regression (nQuery Advisor version 7.0, Statistical Solutions, Saugus, MA). Statistical analysis was performed using IBM SPSS Statistics (version 21.0, IBM, Armonk, NY). A two-tailed p value <0.05 was considered statistical significant.

2. Results

2.1. Patient Characteristics

Twenty patients were identified and met inclusion criteria. Thirty-five percent were female. Median estimated gestational age (EGA) was 37.5 weeks (range: 24–40 weeks). Of the 20 patients, 70% had an associated history of esophageal atresia with and without tracheoesophageal fistula (EA/TEF), 40% had congenital heart disease (CHD), 25% had both EA/TEF and CHD, and 85% had another condition overall. Twenty percent were found to have a tracheal diverticulum at the time of the repair, whereas 2 (10%) were found to have a double aortic arch. Five percent ($n = 1$) were neonates at the time of the repair.

Median weight at the time of operation was 8.5 kilograms (range: 3.8–38.8 kilograms). Median age of the patient at the time of the operation was 14 months (range: 2–196 months) (Table 1). Five percent (n = 1) had a previous aortopexy at an outside institution.

2.2. Operative Indications and Characteristics

Twelve (60%) of the patients had preoperative CT scans determining the point of maximum collapse and/or intrusion, as well relationship to mediastinal vascular structures and presence of persistent tracheal diverticulum (n = 4, 20%). All had had preoperative endoscopic exams. The operative approach was determined by the surgeon, using median sternotomy in 57%, 38% by thoracotomy, and 5% utilizing both. The tracheobronchopexy performed was guided by preoperative imaging, endoscopic exam and determined by the surgeon. Six patients (30%) underwent an isolated anterior tracheobronchopexy, 10 patients (50%) had an isolated posterior tracheobronchopexy and 4 patients (20%) required both. Additionally, nine patients (45%) underwent left main bronchopexy (Table 1). Two patients required a 2-stage approach to their direct tracheobronchopexy.

2.3. Hospital Course, Complications, Anatomic Evaluation and Follow-Up

Median total hospital stay was 26 days (range: 3–336 days). Median total intensive care unit (ICU) stay was 4.5 days (range: 1–336 days).

Table 1
Patient clinical characteristics and conditions.

Variable	N (% or range)
Estimated gestational age (weeks)	37.5 (range, 24–40)
Male:female	13:7
Median age at repair (months)	8.5 (range, 3.8–38.8)
Neonate (<30 days)	1
Infant (30 days–1 year)	8
Child (>1 year)	11
Patient conditions	
Esophageal atresia	
Esophageal atresia	9
Long-gap esophageal atresia	5
Tracheoesophageal fistula	10
Tracheal diverticulum	4
VACTERL	2
Cardiac conditions	
Ventricular septal defect	4
Atrial septal defect	5
Coarctation	1
Pulmonary artery dilation	1
Double aortic arch	2
Type 1 laryngeal cleft	1
CCAM	1
Surgical technique and hospital characteristics	N (% or range)
Tracheobronchopexy	
Primary procedure	9 (45%)
Combined procedure	11 (55%)
Tracheobronchopexy approach	
Anterior	6 (30%)
Posterior	10 (50%)
Both	4 (20%)
Cardiopulmonary bypass used (n = 6)	6 (30%)
CPB (median) (min)	85 (range, 48–155)
CCT (median) (min)	68 (range, 14–93)
Median	
Total hospital duration (days)	26 (range, 3–336)
ICU duration (days)	4.5 (range, 1–336)
Total days on ventilator	2 (range, 0–20)
Number of bronchoscopies	2.5 (range, 1–10)

CPB – cardiopulmonary bypass; CCT – cross-clamp time; ICU – intensive care unit; VACTERL – CCAM.

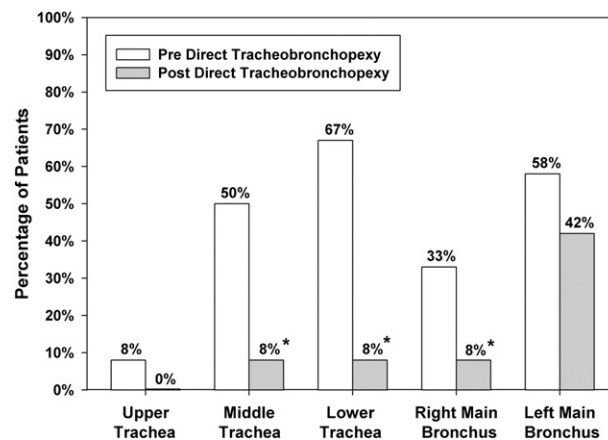


Fig. 2. Surgical outcomes following direct tracheobronchopexy.

Median days on the ventilator were 2 days (range: 0–20 days) (Table 1). There were no significant early complications including hemorrhage or infection. One patient developed a chylothorax but was medically managed and resolved without intervention. There were no early or late deaths.

Median number of bronchoscopies per patient was 2.5 bronchoscopies (range: 1–10 bronchoscopies). Additional anatomic follow-up evaluation with bronchoscopy was completed in 18 of the 20 patients. Ninety percent (n = 18) of patients underwent follow-up bronchoscopy at a median of 2 months (range, 1–11 months). Logistic regression modeling illustrated a significantly lower percentage of patients with tracheobronchomalacia at postoperative endoscopic exam for the following anatomical regions: (a) middle trachea (p = 0.01); (b) lower trachea (p < 0.001); and, (3) right main bronchus (p = 0.04) (Fig. 2).

All patients had follow-up at a median of 5 months (range: 0.5–38 months). At latest follow-up, no patients had a recurrence of an ALTE. There were significantly fewer documented pneumonias; 80% vs. 20% (p = 0.0005) and there was a trend toward less supplemental oxygen (p = 0.375) (Fig. 3). No patient who underwent posterior tracheopexies had documented postoperative pneumonias (n = 0, 0%) and 1 (10%) patient was on oxygen postoperatively; percentages were also documented for those who underwent anterior and both and anterior and posterior tracheopexies in Table 2.

3. Discussion

The incidence of tracheomalacia (TM) or tracheobronchomalacia (TBM) is approximately 1 in 2100 children is likely an underestimation given the associated infant mortality and misdiagnosis [2]. Certain patient groups tend to be affected more often by TBM than the general population given the anatomical interrelationships between the trachea, major bronchi, esophagus, and the heart along with the great vessels. Currently there is no consensus regarding radiographic evaluation, standardized endoscopic evaluation, surgical approach, and medical treatments for significant TBM. Furthermore, according to the 2012 Cochrane review [13], there is currently no evidence supporting one therapy over another for the treatment of TBM [13].

In efforts to standardize the diagnosis and treatment of TBM at our institution, we have initiated a process for the classifications made at the time endoscopic exams and have created a multidisciplinary approach to these patients [10]. TM and TBM are characterized by excessive collapsibility of the airways; typically occurring during expiration [14]. The greater the severity of airway collapse may portend earlier operative intervention. In this series of 20 patients, we show that the use of direct tracheobronchopexy, with either anterior suspension and/or

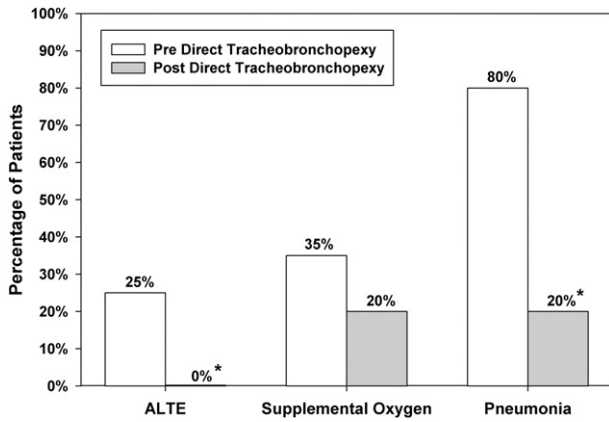


Fig. 3. Title clinical outcomes following direct tracheobronchopexy.

posterior fixation for severe TBM, resulted in anatomic correction and resolution of ALTEs at follow-up and also significantly reduced the incidence of recurrent pneumonias.

Either open aortopexy, or more recently, thoracoscopic aortopexies, has been used to treat TM and TBM [14–16]. Other operative options have included surgical lateropexia, tracheal reconstruction, external stabilization, tracheostomies and suspensions [14,17]. The goal in these is anterior fixation or stabilization of the central airways and major bronchi. Yet, in one recent report, this meta-analysis of aortopexies suggested that the overall complication rate was 15%, 8% of patients reported no changes in symptoms, 6% died, and 4% of patients reported worsening symptoms [18]. These analyses have their own limitations, but certainly indicate that there is room for improvement. Our short-term outcomes have illustrated no overt complications, no deaths, and an improvement in symptoms.

We have observed a common feature during the endoscopic evaluation of these patients in that aortopexy may often not directly address either malformed tracheal cartilage and/or posterior airway intrusion caused by the membranous component. In fact, it may be that the anterior cartilaginous component of the trachea is a fixed and stenotic lesion; whereas, the posterior membranous component of the trachea is more of a dynamic lesion. More than 50% of our patient population underwent direct posterior tracheobronchopexy and 20% required both anterior and posterior tracheobronchopexies to relieve severe airway collapse. This approach does not rule out the concomitant use of aortopexy. These operations may be needed and performed simultaneously and/or staged if indicated, along with occasional pexy of the pulmonary arteries (PA) in some cases; in our cohort this happened in 2 cases.

Our cohort represents one of the largest series in the pediatric literature showing that the addition of either an anterior tracheopexy and/or posterior tracheopexy contributes to reestablishing the normal airway anatomy, prevents complete coaptation of the major airways on expiration, and allows for proper mucociliary function and improved respiratory mechanics [19–21]. Surgical dilemmas we have encountered

in these patients have been the refractory nature of the collapsed left mainstem bronchus, identifying and protecting the thoracic duct, and continued need for oxygen and medications in some patients. The difficulty in opening the left mainstem bronchus is probably a consequence of using a right thoracotomy and the resulting inaccessibility of the left mainstem bronchus. The thoracic duct should be avoided to limit this potentially significant complication. With time and firming up of an opened airway, the need for oxygen supplementation and medications should become less.

There are a number of limitations that need to be addressed for this study. First, this is a small, retrospective study. Secondly, our cohort included complex patients who required many distinct adjunct medical therapies, which may have contributed to outcomes and confounded the influence of our surgical treatment plans alone. Thirdly, complete radiographic evaluations were not available on all the patients; however, we were able to utilize a standardized bronchoscopic scoring system to evaluate TBM and its subsequent resolution postoperatively. This has proven to be equally as efficacious, while at the same time limiting radiation in a pediatric population [10]. Finally, follow-up intervals were variable, and relatively short term. Our short-term outcomes have been very encouraging, and we will continue to follow these patients long term to assess any additional benefits or pitfalls of the multidisciplinary approach.

4. Conclusions and Future Directions

In this series of 20 patients, the use of direct tracheobronchopexy for severe TBM resulted in resolution of ALTEs at follow-up, and also significantly reduced the incidence of recurrent pneumonia. Direct tracheobronchopexy resulted in significant reduction in TBM in the middle and lower tracheal segments, as well as the right mainstem bronchus. Given the heterogeneity of this population, larger studies are needed to ascertain longer-term outcomes of this technique on specific segments of the trachea and bronchial tree, develop a prospective grading score for severity as well as collapse, and correlate this with quality of life-related health issues.

References

- [1] Jennings RW, Hamilton TE, Smithers CJ, et al. Surgical approaches to aortopexy for severe tracheomalacia. *J Pediatr Surg* 2014;49:66–71.
- [2] Fischer AJ, Singh SB, Adam RJ, et al. Tracheomalacia is associated with lower FEV1 and *Pseudomonas* acquisition in children with CF. *Pediatr Pulmonol* 2013. <http://dx.doi.org/10.1002/ppul.22922> [Epub ahead of print].
- [3] Weber TR, Keller MS, Fiore A. Aortic suspension (aortopexy) for severe tracheomalacia in infants and children. *Am J Surg* 2002;184:573–7.
- [4] Vasquez-Jimenez JF, Schweh JS, Liakopoulos OJ, et al. Aortopexy in severe tracheal instability: short term and long-term outcome in 29 infants and children. *Ann Thorac Surg* 2001;72:1898–901.
- [5] Greenholz SK, Karrer FM, Lilly JR. Contemporary surgery of tracheomalacia. *J Pediatr Surg* 1986;21:511–4.
- [6] Kamata S, Usui N, Sawai T, et al. Pexis of great vessels for patients with tracheobronchomalacia in infancy. *J Pediatr Surg* 2000;74:315–9.
- [7] Dave S, Currie BG. The role of aortopexy in severe tracheomalacia. *J Pediatr Surg* 2006;41:533–7.
- [8] Carden KA, Boiselle PM, Waltz DA. Tracheomalacia and tracheobronchomalacia in children and adults: an in-depth review. *Chest* 2005;127:984–1005.
- [9] Filler RM, Messineo A, Vinograd I. Severe tracheomalacia associated with esophageal atresia: results of surgical treatment. *J Pediatr Surg* 1992;27:1136–41.
- [10] Ngercham M, Lee EY, Zurakowski D, et al. Tracheobronchomalacia in pediatric patients with esophageal atresia: comparison of diagnostic laryngoscopy/bronchoscopy and dynamic airway multidetector computed tomography. *J Pediatr Surg* 2015 Mar;50(3):402–7. <http://dx.doi.org/10.1016/j.jpedsurg.2014.08.021> [Epub 2014 Oct 1].
- [11] Vittinghoff E, Glidden DV, Shiboski SC, et al. *Regression methods in biostatistics. Linear, logistic, survival, and repeated measures models*. New York: Springer; 2005 253–80.
- [12] Altman DG. *Practical statistics for medical research*. Boca Raton, FL: Chapman & Hall; 1991 258–64.
- [13] Goyal V, Masters IB, Chang AB. Interventions for primary (intrinsic) tracheomalacia in children. *Cochrane Database Syst Rev* 2012;10:CD005304. <http://dx.doi.org/10.1002/14651858.CD005304.pub3>.

Table 2

Persistent symptoms following direct tracheobronchopexy.

Variant of direct tracheobronchopexy	n	Postoperative pneumonia	Postoperative oxygen	Postoperative ALTE
Anterior direct pexy	6	2 (30%)	2 (33.3%)	0 (0%)
Posterior direct pexy	10	0 (0%)	1 (10%)	0 (0%)
Both anterior and posterior pexy	4	2 (50%)	1 (25%)	0 (0%)

- [14] Kugler C, Stanzel F. Tracheomalacia. *Thorac Surg Clin* 2014;24(1):51–8. <http://dx.doi.org/10.1016/j.thorsurg.2013.09.003>.
- [15] van der Zee DC, Bax NM. Thoracoscopic tracheo-aortopexia for the treatment of life-threatening events in tracheomalacia. *Surg Endosc* 2007;21(11):2024–5 [Epub 2007 Mar 14].
- [16] Perger L, Kim HB, Jaksic T, et al. Thoracoscopic aortopexy for treatment of tracheomalacia in infants and children. *J Laparoendosc Adv Surg Tech A* 2009;19(Suppl 1):S249–54. <http://dx.doi.org/10.1089/lap.2008.0161.supp>.
- [17] Yokoi A, Arai H, Bitoh Y, et al. Aortopexy with tracheal reconstruction for postoperative tracheomalacia in congenital tracheal stenosis. *J Pediatr Surg* 2012;47(6):1080–3. <http://dx.doi.org/10.1016/j.jpedsurg.2012.03.009>.
- [18] Torre M, Carlucci M, Speggiorin S, et al. Aortopexy for the treatment of tracheomalacia in children: review of the literature. *Ital J Pediatr* 2012;38:62. <http://dx.doi.org/10.1186/1824-7288-38-62>.
- [19] Majid A, Guerrero J, Gangadharan S, Feller-Kopman D, Boisselle P, DeCamp M, Ashiku S, Michaud G, Herth F, Ernst A. Tracheobronchoplasty for severe tracheobronchomalacia: a prospective outcome analysis. *Chest* 2008 Oct;134:801–7. <http://dx.doi.org/10.1378/chest.08-072>.
- [20] Wright CD, Grillo HC, Hammoud ZI, et al. Tracheoplasty for expiratory collapse of central airways. *Ann Thorac Surg* 2005;80(1):259–66.
- [21] Wang CC, Lu CW, Chen CA, et al. One-stage repair of ventricular septal defect and severe tracheomalacia by aortopexy and posterior tracheal wall stabilization. *Ann Thorac Surg* 2010;89:1677–8.